



Computer-assisted extra-articular distal radius osteotomies using patient-specific surgical guides

Vasilii Shishkin and Valeriy Golubev

Central Clinical Hospital of the Russian Academy of Sciences, Moscow, Russia
vb@shishkin.su

Abstract

Malunions of the distal radius are often treated with correction osteotomies, which can be challenging to perform.

In this report, 23 patients with symptomatic distal radius malunions were treated using 3D printed patient-specific surgical guides to facilitate surgery. Patients were compared with a control group of 23 patients that underwent similar surgery with a conventional x-ray planning approach.

Postoperatively all patients in the computer-assisted group showed recovery of ROM, with no anatomical abnormalities on x-ray examination. 6 patients in the conventional planning group had reduced ROM with a residual volar tilt on x-ray images.

Computer-assisted planning with the use of 3D printed patient-specific surgical guides enhances results of corrective osteotomies of distal radius malunions.

1 Introduction

Malunions of distal radius fractures is still the most common complication after wrist fractures, with overall malunion rates as high as 17% [1]. Symptomatic malunions of the distal radius are often treated with correction osteotomies [2]. However, complex bone deformities can often be difficult to identify as these measures are not completely addressed by conventional preoperative planning techniques. At the same time, accuracy of the anatomical reconstruction is essential to achieving optimal functional results [3].

2 Materials and Methods

From January 2014 to January 2018 23 patients with symptomatic distal radius malunions were treated in our hospital using a computer-assisted preoperative planning technique. We compared these patients with a control group that consisted of 23 patients with similar deformities that underwent

surgery with a conventional planning approach. The computer-assisted group underwent a CT scan of the injured forearm as well as the contralateral, healthy extremity preoperatively. Using the acquired CT data, 3D anatomical models were created in specialized open source segmentation software. After that, both models were superimposed and the planning process was carried out in MARS, a computer program developed by our team, implementing an iterative closest point computer algorithm for accurate automatic repositioning of bone fragments. A patient-specific surgical guide was then produced on a 3D printer out of a biologically compatible material to transfer the planned correction to the operation room. The guide was used for adequate positioning of the osteotomy plane and pre-drilling of plate screw holes. The fixation plate itself served as a repositioning device: screws were inserted in the appropriate pre-drilled holes thus positioning the fragments in the preoperatively planned manner (Figure 1).

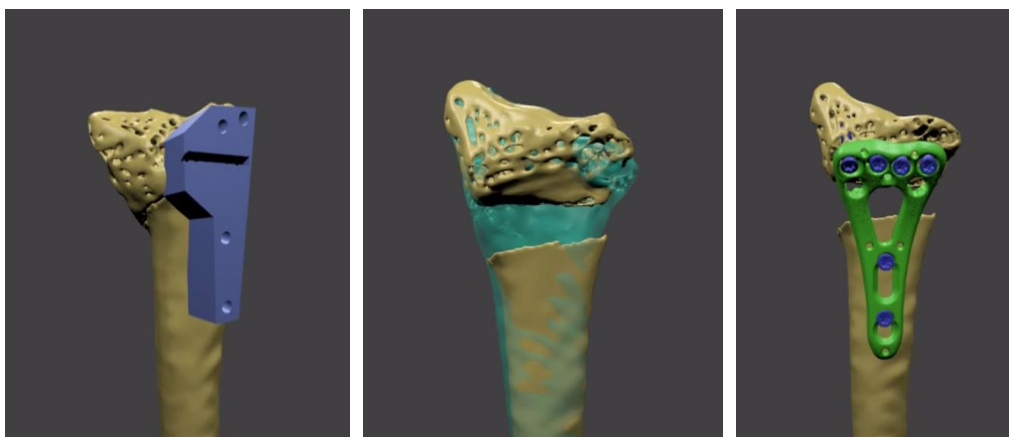


Figure1: From left to right: Osteotomy guide positioned on radius, distal fragment positioned over healthy bone model, fragments fixed with plate

The computer planning and surgical guide manufacturing process was performed in-house, at the clinic where the surgery was carried out. The control group had x-rays of the affected region taken in AP and lateral views as a preoperative assessment tool. In both groups volar locking plates of the same manufacturer were used. We examined the postoperative x-rays, range of motion (ROM) and Disabilities of the Arm, Shoulder and Hand (DASH) score at 3, 6 and 12 months postoperatively in both groups.

3 Results

At 3 months postoperatively all patients in the computer-assisted group showed recovery of ROM, with no statistically significant difference in extension, flexion, supination and pronation compared with the contralateral side. We found the achieved ROM to be better than mentioned in the previous studies with computer-assisted 3D planned corrective osteotomy in radial malunions [4, 5]. Six patients in the conventional planning group had reduced ROM compared with the contralateral side. Examination of postoperative x-rays revealed a residual volar tilt in these patients. The computer-assisted group had no anatomical abnormalities detected on x-ray. At 12 months postoperatively there were no significant differences in ROM in both groups the mean DASH score was 11,4 in the

computer-assisted group, while the control group had a mean score of 16,2. Patients in both groups had total pain relief. Besides patient functional outcomes and x-ray findings, reduced time of surgery and intraoperative radiation exposure was noted in the computer-assisted group.

4 Discussion

The postoperative range of motion in this report was found better than in previous studies on using patient-specific surgical guides for corrective osteotomy in distal radius malunions [4, 5]. This may be due to the fact, that this study addresses only extra-articular distal radius malunions. The achieved functional results in the main group were superior not only to our control group, but also to the published results of conventionally planned corrective osteotomies of the distal radius [6].

Summarizing the above, computer-assisted planning with the use of 3D printed patient-specific surgical guides enhances results of corrective osteotomies of the distal radius, facilitating transfer of the computer-generated plan to the operating room. The proposed technology provides more accurate surgery performance and has shown good 12-months functional outcome results, while reducing surgery time and intraoperative radiation exposure.

5 References

1. Amadio PC, Botte MJ (1987) Treatment of malunion of the distal radius. *HandClin*, 3(4):541-61
2. Buijze G, Prommersberger K-J, Gonzalez Del Pino J, Fernandez DL, Jupiter JB (2012) Corrective osteotomy for combined intra and extra-articular distal radius malunion. *J Hand Surg Am*. 37:2041–2049. doi:10.1016/j.jhsa.2012.07.013
3. Vroemen JC, Dobbe JGG, Strackee SD, Streekstra GJ (2013) Positioning evaluation of corrective osteotomy for the malunited radius: 3-D CT versus 2-D radiographs. *Orthopedics* 36:e193–e199. doi:10.3928/01477447-20130122-22
4. Athwal GS, Ellis RE, Small CF, Pichora DR (2003) Computer assisted distal radius osteotomy. *J Hand Surg Am* 28:951–958. doi:10.1016/S0363-5023(03)00375-7
5. Miyake J, Murase T, Oka K, Moritomo H, Sugamoto K, Yoshikawa H (2012) Computer-assisted corrective osteotomy for malunited diaphyseal forearm fractures. *J Bone Joint Surg* 94:1–11
6. Lozano-Calderón SA, Brouwer KM, Doornberg JN, Goslings JC, Kloen P, Jupiter JB (2010) Long-term outcomes of corrective osteotomy for the treatment of distal radius malunion. *J Hand Surg Eur Vol.*, 35(5):370-80